



Ayurvedic management of Pregnancy Induced Bilateral Carpal Tunnel Syndrome: A Case Study

Karthika Kannammuri Jayan*

Received: 07.07.2024

Revised: 02.08.2024

Accepted: 23.10.2024

ABSTRACT: Carpal Tunnel Syndrome (CTS) is a common condition encountered in third trimester of pregnancy due to hormonal changes, weight gain and fluid retention. Repeated stress while breastfeeding and caring for newborn aggravate the condition and delay healing during child-nursing period. The prevalence in CTS cases is reported to be as high as 62%. As per previous studies, even with standard care symptoms persist even after three years in many.

Brief case report: A 30-year-old female advised for surgical decompression after diagnosis with pregnancy induced bilateral CTS. In *ayurveda* it was correlated as *snaayugata vaata*(~*vaata* affecting ligaments) and the patient was administered a fifteen-day course of ayurvedic treatments comprising of *dhaanyamla dhaara* (Pouring of warm fermented herbal decoction), *upanaaha* (bandaging) *sthaanika jambeerapinda sveda* (lemon poultice) and *picu* (patch of medicated oil) with exercises. The progress of the condition was evaluated with The Boston Carpal Tunnel Syndrome Questionnaire.

Conclusion: Significant progress was observed on assessment with The Boston Carpal Tunnel Syndrome Questionnaire. The quality of life of the patient improved without undergoing the suggested surgical decompression.

Key words: Wrist problems, diseases during pregnancy, Bilateral Carpal Tunnel Syndrome, Ayurveda during pregnancy.

INTRODUCTION

CTS, an entrapment neuropathy of median nerve at wrist, manifested as paraesthesia, numbness, and pain along the nerve distribution which may progress to atrophy of the hand muscles with symptoms worsening at night.^[1] Most cases are idiopathic except ones related to occupational or environmental associations. Gestational hypertension, pre-eclampsia, greater BMI, increased maternal age, diabetes mellitus, history of smoking and alcohol, non-Caucasian ethnicity, CTS in previous pregnancy are predisposing factors.^[2] In *ayurveda* CTS symptoms are similar to *snaayugata-vaata*(*vaata* affecting ligaments) and it responded significantly when managed with modalities of *snehana* (oleation) and *swedana* (fomentation).

Case report

A 30-year-old female, Indian, a resident of Dubai, consulted the OPD on 21/12/2023 with the complaints of pain in both the wrists associated with feeling of numbness, heaviness and weakness of both the hands. There were altered tactile sensation, predominantly in the right hand, worse for the past one week. The patient had no other relevant medical diagnoses or notable habits. Vitals were within the normal range.

History of present illness

Patient was apparently normal till the eighth month of pregnancy. Gradually she developed mild tingling sensation of the right hand which usually set relieved as she was involved in activities for about fifteen minutes. Mild pain persisted in the

1. Pranavam, Kannanmuri House, Ashoka Road, North End, Kaloor, Kochi 682017
Email: karthikajayan@yahoo.com

right wrist which got better with self-opted sessions of post-partum massage therapies for a duration of three months. By the fourth month after delivery she noticed difficulty while brushing the teeth and gradually developed pain in the right wrist. Both the wrists were affected shortly. The pain in her right wrist was excruciating and radiated till the right lateral aspect of her neck. Soon the condition was associated with marked tingling sensation, heaviness and numbness of both the hands. Hand massages gave mild relief. She couldn't sleep due to pain. Gradually she felt altered tactile sensation in the fingers of her right hand following which she consulted a doctor who advised her a nerve conduction study. The study was suggestive of bilateral distal median neuropathy at wrist suggestive of bilateral CTS (Right severe and left mild). She was prescribed internal mediations and was advised to undergo decompression surgery which she didn't prefer and opted for ayurvedic treatments.

Examination

On examination there was restricted range of movement (ROM) of the right wrist. Left wrist had normal ROM. Tinel's sign was positive on both the sides, but the pain also radiated towards the upper arm while tapping on the nerve at the right wrist. The nerve conduction study report was already conclusive of bilateral carpal tunnel syndrome with severity on the right side.

Dasavidha pareeksha (10-fold ayurvedic examination)

Prakṛti : kapha paittika

Vikṛti : vaata kaphaja

Saara : madhyama

Samhanana : madhyama

Pramaana : madhyama

Saatmyam : madhyama

Satvam : madhyama

Aahara śakti : madhyama

Vyaayaama śakthi : madhyama

Vayah : madhyama

| Table 1 Treatment details | | | |
|--|--|---|----------|
| Procedure | Description | Medication | Duration |
| <i>Sthaanika</i> (local) <i>dhaanyamla dhaara</i> and <i>upanaaha</i> on both wrists | Pouring of warm fermented herbal decoction is known as <i>dhaanyamla dhaara</i> . <i>upanaaha</i> is bandaging with warm herbs. | Naagaraadi coornam with marmagulika and egg white for bandage | 3 days |
| <i>Sthaanika</i> (local) <i>jambheerapinda svedam</i> (neck to both hands) + Oil Bandage (both wrists) | Lemon poultice | Karpaasastyadi taila with <i>Murivenna</i> for bandaging | 7 days |
| <i>Picu</i> | Lukewarm medicated oils soaked in a cotton pad is kept on the affected area and retained till the temperature comes down is called <i>picu</i> . | Karpaasastyaditaila with <i>Murivenna</i> . | 5 days. |

Treatment plan

Extensor tendon gliding exercise and Neural glide exercise were coupled with therapy from the third day of oil-based sessions, i.e., day 6 of the therapy.

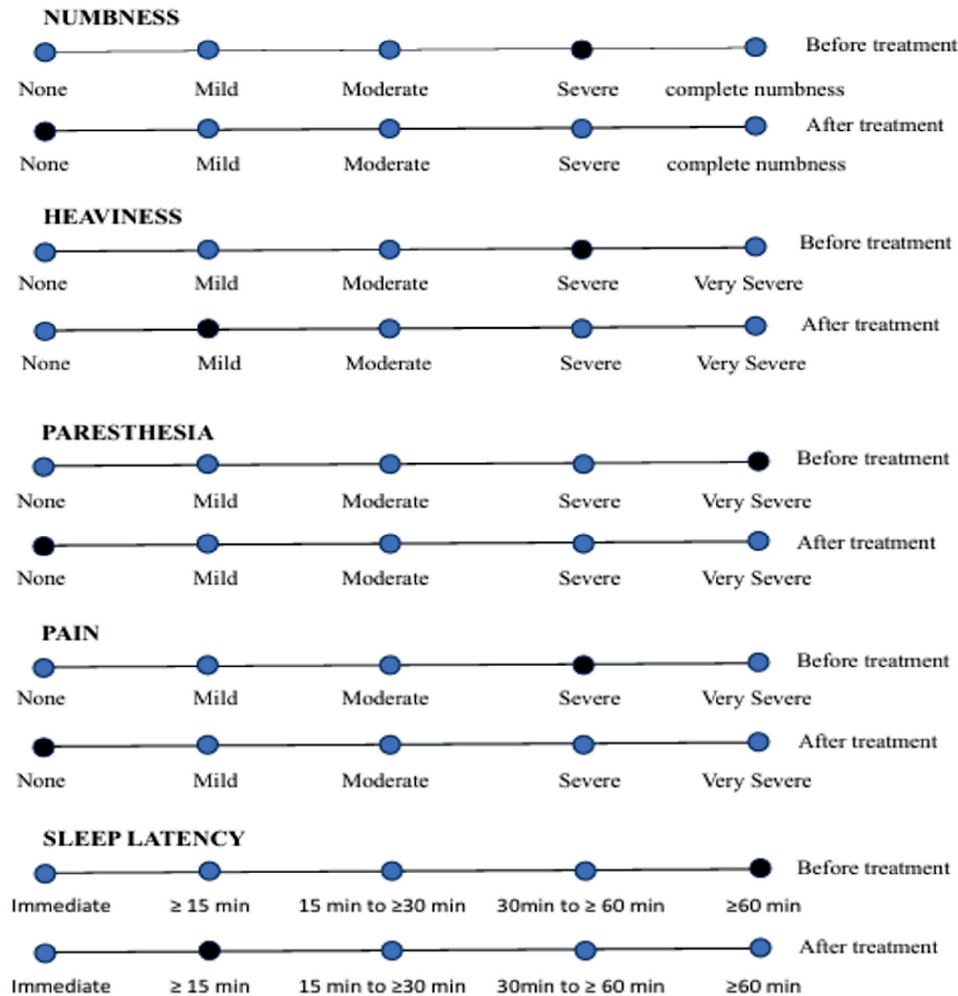
OBSERVATION AND RESULTS

After fifteen days of external therapies the patient got significant relief from the condition. The Boston symptom severity scale (SSS) and functional status scale (FSS) of the patient were assessed before and after treatment. Before treatment SSS was 3.090 for the right hand and 1.545 for the left hand. After treatment it was 1.091 (right and left). FSS was 3.375 before

treatment and 1.25 after treatment. There was marked improvement for the numbness, tingling sensation and pain. Mild weakness and heaviness

persisted in the right hand but the patient never experienced difficulties at night after the treatment. Visual Analogue Scale was also used

Figure 1
Gradation of Symptoms



to evaluate the response of treatment. The following response was observed.

Follow - up

The patient was requested for follow-up visit three months after the treatment. There was no necessity of any additional interventions as the condition remained stable.

DISCUSSION

CTS and De Quervain disease are the two predominant pregnancy induced hand and wrist conditions, others being neuralgic amyotrophy,

ligamentous laxity, exacerbation of arthritic conditions, pyogenic granuloma of hand, etc.^[2] The flexor retinaculum (FR) and the carpal bones make the carpal tunnel with FR forming its roof. The nine flexor tendons, their sheath and median nerve pass through this osteo-fibrous outlet.^[4] The pathophysiology of pregnancy induced CTS is not understood. There is a strong hypothesis stating that alterations induced in transverse carpal ligament from relaxin causes narrowing of carpal tunnel there by inducing CTS.^[5] Repetitive wrist movements can also cause fibrous hypertrophy

of the synovial flexor sheath which can cause entrapment of median nerve resulting in CTS.^[4] Pregnancy induced CTS has a good prognosis. Even though the nerve conduction studies turn normal with time, CTS symptoms might themselves resolve after few weeks of pregnancy especially with weight loss of mother. However, >50 % females experience symptoms even after one year and approximately 30% after three years.^[2]

Any fibrous connective tissues in the body viz; tendons, aponeurosis, fascia, peripheral nerves, ligaments are considered as *snaayu*. The treatment modalities like *sneha* (oleation), *upanaaha* (poltices), *agnikarma* (cautery), *bandhana* (bandaging), *mardana* (massage) are elaborated in *ayurveda* for the management of various ailments pertaining to these structures.^[6] Here CTS was diagnosed as *snaayugata vaata* (vaata affecting ligaments) and the line of treatment was opted accordingly.

Dhaanyamla dhaara is best suited in treating conditions with a *kapha*-*vaata* predominance.^[7] Inflammatory changes and muscular pain reduce considerably after *parisheka* (pouring liquid) with this fermented liquid. It also activates nerves.^[8] In *upanaaha* (bandaging) the patient was advised to retain the bandage for twelve hours. It has the potential to reduce any local pain and swelling.^[9] Anti-inflammatory and analgesic properties are observed for Naagaraadi coornam.^[10] The pain resulting from injuries to vital structures can be well managed with application of Marmagulika which is a formulation containing thirty five drugs.^[11] Thus this combination of medications was chosen in the initial phase of the treatment to reduce soft tissue swelling and pain. *Soolaghna* (analgesic) and *sotha-hara* (anti-inflammatory) properties are attributed to *jambheera-pinda sveda* (lemon poultice). It mainly helps pacify *vaata* and *kapha*.^[12] Murivenna is proven to have significant results in restoring functional loss especially in studies conducted w.r.t sports injuries.^[13] Kaarpaasastyadi tailam is processed

with *vaata-hara* (pacify *vaata*) ingredients.^[14] This oil belonging to the traditional Kerala ayurvedic practice, used for treatment of paralysis, facial palsy, spondylosis and other neuromuscular conditions.^[15] Thus the combination of Kaarpaasastyadi tailam and Murivenna was chosen in the second stage of treatment to improve the ROM of the wrist. By the continuous oleation and sudation therapy the flexibility of the joints improved, thus the extensor tendon gliding and neural glide exercises were included from the sixth session for better results. On observing improvement in the symptoms, the *jambheerapinda svedam* (lemon poultice) was stopped and the *picu* (patch of medicated oil) sessions were started. Local action of *picu* is based on cellular absorption of medicine.^[16] This was continued for five days and stopped as there was significant improvement for the condition. In the *parihaara kaala* (post treatment phase) patient was requested to wear wrist brace for another two weeks and continue the exercises.

CONCLUSION

After analysing various descriptions in the classics CTS was managed in the line of *snaayugata-vaata* (Vaata affecting ligaments) and treatment modalities like *snehana* (oleation), *svedana* (fomentation), *upanaaha* (bandaging) and *mardana* (massage) were opted here which proved to be very effective in the management of CTS. Without surgical decompression, conservative ayurvedic management could alone relieve the symptoms and thereby improve the quality of life of the patient. The non-medical massage services opted by the patient could provide the patient temporary relief. Timely adoption of *sootikaa-paricarya* (ayurvedic post natal care) with specific modifications according to the condition of patient could have had potential impact in early resolution of symptoms.

References

1. Robert L. Barbieri, John T. Repke, Harrison, s Principle of Internal Medicine, 20th edition, Chapter 466, *Medical*

- disorders during pregnancy*, page 3444, The McGraw-Hill Companies, New York; 2018.
2. Afshar A, Tabrizi A. Pregnancy-related Hand, and Wrist Problems. *Arch Bone Jt Surg*. May;9(3):345-349, 2021 doi: 10.22038/abjs.2020.50995.2531. PMID: 34239963; PMCID: PMC8221449
 3. Vd.Harish Chandra Singh Kushwaha (Ed.) *Caraka Samhita, Chikitsa Sthana, Vol 2, vatavyadhi chikitsa, Chapter 28, Verse 35, Page No.730*, Reprint edition 2017, Chaukhambha Orientalia, Varanasi,
 4. Aboonq MS. Pathophysiology of carpal tunnel syndrome. *Neurosciences* (Riyadh). 2015 Jan;20(1):4-9. PMID: 25630774; PMCID: PMC4727604.
 5. Scott JR, DiSaia PJ, Hammond CB, Spellacy WN. *Danforth's Obstetrics and Gynecology*, 19th ed. JB Lippincott, Philadelphia; 1990
 6. Shilpa R. Revale. Elaborate the Concept of 'Snayu' from Shushrut Samhita. *Ayushdhara*, 9(3):87-90, 2022.
 7. Vandana, Alok Kumar Srivastava, Meenakshi Gusain, Priyanka. Efficacy of Dhanyamla Sarvanga Dhara in the Management of Obesity: An Analytical Review. *International Journal of Ayurveda and Pharma Research*. 6(6):81-84, 2018.
 8. Raghuram Y.S. *Dhanyamla Dhara, Kanjidhara: Benefits procedure article* /03/02, 2016, <https://easyAyurveda.com>.
 9. Shaikh Akhil Shaikh Chand, Tabassum Kauser Iqbal Ahmed Khan² and Harshaprabha P. Katole. Upnaha swadana a review article with special reference to bandaging. *World journal of pharmaceutical and medical research*. 9(1), 56-59, 2023.
 10. Anekkallil Gopalan Vaidyan (Ed.) *Sahasrayogam*. (A traditional compilation of ayurvedic formulations practised by ayurvedic physicians in Kerala).: Vidyarambham Publications, Alappuzha, 2016.
 11. Nishteswar K, Vidyanath R, *Sahasrayogam. Gutikayog Prakaran.*: p. 436e632, Chaukhambha Sanskrit series office; Varanasi, 2006.
 12. Brahmasankara M, Rupalalaji V, ed. *Bhavaprakasha of Bhavamishra, Part-I, Purvakhanda*, ch. 5, Ver. 316, . p. 150 Chaukhambha Sanskrit Sansthan; Varanasi: 2004.
 13. S. Sharma, R. Killedar, D. Bagewadi, P. Shindhe Protocol based management of common sports injuries by integrated approach of Sandhi Marmabhighata – an open labeled clinical trial *J Ayurveda Integr Med*, pp. 119-125, 10.1016/j.jaim.2020.12.009, 12 (1) 2021.
 14. Singh Sapna et al: Therapeutic role of Karpasasthyadi Tailam Nasya in the management of Manyastambha (cervical spondylosis). *International Ayurvedic Medical Journal* {online} {cited September 2023}
 15. <https://www.ayurmedinfo.com/2012/06/02/karpasasthyadi-thailam-benefits-how-to-use-ingredients-side-effects>.
 16. Meda Mruthyumjaya Rao, P. Hemantha Kumar, Purnendu Panda, Bikartan Das. Comparative Study of Efficacy of Jatyadi Ghrita Pichu and Yasthimadhu Ghrita Pichu in the Management of Parikartika (Fissure- In-Ano). *International Journal of Ayurveda and Pharma Research*. 4(2):1-9, 2016.